Review

David A. Lynch, MD
William D. Travis, MD
Nestor L. Müller, MD, PhD
Jeffrey R. Galvin, MD
David M. Hansell, MD
Philippe A. Grenier, MD
Talmadge E. King, Jr, MD

Published online
10.1148/radiol.2361031674
Radiology 2005; 236:10–21

Abbreviations:
AIP = acute interstitial pneumonia
COP = cryptogenic organizing pneumonia
DIP = desquamative interstitial pneumonia
IIP = idiopathic interstitial pneumonia
LIP = lymphoid interstitial pneumonia
NSIP = nonspecific interstitial pneumonia
RB-ILD = respiratory bronchiolitis–associated interstitial lung disease
UIP = usual interstitial pneumonia

[1] From the Department of Radiology, University of Colorado Health Sciences Center, CB A-030, 4200 E Ninth Ave, Denver, CO 80262 (D.A.L.); Departments of Pulmonary and Mediastinal Pathology (W.D.T.) and Radiology (J.R.G.), Armed Forces Institute of Pathology, Washington, DC; Department of Radiology, Vancouver General Hospital, University of British Columbia, Vancouver, British Columbia, Canada (N.L.M.); Department of Radiology, Royal Brompton Hospital, London, England (D.M.H.); Department of Radiology, Hôpital Pitié-Salpêtrière, Paris, France (P.A.G.); and Department of Medicine, San Francisco General Hospital, San Francisco, Calif (T.E.K.). Received October 15, 2003; revision requested January 12, 2004; revision received April 29; accepted July 29. **Address correspondence to** D.A.L. (e-mail: *david.lynch@uchsc.edu*).

Authors stated no financial relationship to disclose.

© RSNA, 2005

Idiopathic Interstitial Pneumonias: CT Features[1]

Idiopathic interstitial pneumonias comprise usual interstitial pneumonia (UIP), nonspecific interstitial pneumonia (NSIP), desquamative interstitial pneumonia (DIP), respiratory bronchiolitis–associated interstitial lung disease (RB-ILD), cryptogenic organizing pneumonia (COP), acute interstitial pneumonia (AIP), and lymphoid interstitial pneumonia (LIP). Each of these entities has a typical imaging and histologic pattern, although in practice the imaging patterns may be variable. Each entity may be idiopathic or may be secondary to a recognizable cause such as collagen vascular disease or inhalational exposure. The diagnosis of idiopathic interstitial pneumonia is made by means of correlation of clinical, imaging, and pathologic features. The characteristic computed tomographic (CT) features of UIP are predominantly basal and peripheral reticular pattern with honeycombing and traction bronchiectasis. NSIP is characterized by predominantly basal ground-glass opacity and/or reticular pattern, often with traction bronchiectasis. DIP and RB-ILD are smoking-related lung diseases characterized by ground-glass opacity and centrilobular nodules. COP is characterized by patchy peripheral or peribronchovascular consolidation. AIP manifests as diffuse lung consolidation and ground-glass opacity. LIP is associated with a CT pattern of ground-glass opacity sometimes associated with perivascular cysts.
© RSNA, 2005

The idiopathic interstitial pneumonias (IIPs) are a group of diffuse parenchymal lung diseases that share many features but are sufficiently different from one another to be designated as separate disease entities (1). The general term *idiopathic interstitial pneumonia* includes usual interstitial pneumonia (UIP), nonspecific interstitial pneumonia (NSIP), desquamative interstitial pneumonia (DIP), respiratory bronchiolitis-associated interstitial lung disease (RB-ILD), cryptogenic organizing pneumonia (COP), acute interstitial pneumonia (AIP), and lymphoid interstitial pneumonia (LIP). These entities can be easily distinguished from other forms of diffuse parenchymal lung disease by clinical methods, including history, physical examination, laboratory studies, imaging, and pathologic analysis. However, patterns of lung injury similar or identical to those seen in the IIPs are found in many other conditions, including collagen vascular disease, drug reactions, asbestosis, and chronic hypersensitivity pneumonitis. The term *idiopathic* is reserved for those conditions in which the cause of the lung injury pattern is unknown. The classification does not include other morphologically distinct idiopathic lung diseases such as sarcoidosis and the eosinophilic pneumonias.

There have been several previous classifications of the IIPs (2–4), but none of these has clearly delineated the complementary roles of the pathologist, radiologist, and clinician in diagnosing these conditions. Because of substantial variation in the definition and terminology of the IIPs, the American Thoracic Society and the European Respiratory Society convened an international committee of pulmonologists, thoracic radiologists, and pulmonary pathologists to clarify the nomenclature and typical patterns of these conditions. The classification was published in full in the *American Journal of Respiratory and Critical Care Medicine* in 2002 (1). The purpose of the present review is to illustrate the aspects of this classification that are of importance to the radiologist. In particular, we will delineate the typical radiologic features of these entities, with radiologic-pathologic correlation, and review the radiologic differential diagnoses.

Although the new classification is based on histologic criteria, there is a clear recognition that the pattern at thin-section computed tomography (CT) is important in delineat-

ESSENTIALS

- *The classification of IIPs is based on histologic criteria; each histologic pattern is associated with a characteristic imaging pattern that correlates well with the histologic findings.*
- *Similar morphologic patterns of lung injury may occur in other conditions, including collagen vascular disease, hypersensitivity pneumonitis, and drug toxicity; these conditions must be excluded clinically.*
- *In the correct clinical context, the CT features of UIP and organizing pneumonia are often diagnostic.*
- *Distinction of UIP from the other interstitial pneumonias is important because UIP is associated with a substantially poorer prognosis than the other entities.*
- *The role of the radiologist is to identify the macroscopic morphologic pattern and to work with the clinician and pathologist to generate an integrated clinical diagnosis.*

ing the macroscopic morphology of the IIPs (Table 1). The prototypic CT features of each IIP are distinct, though with some overlap. Each IIP pattern seen at histologic examination or CT is linked to a specific idiopathic clinical syndrome (Table 2). However, the differential diagnosis of IIPs usually includes underlying collagen vascular disease or inhalation exposures, and the clinician has a critical role in identifying these causes of lung injury.

Because morphologic patterns identified by pathologists and imagers can be due to a variety of causes, clinical evaluation is essential to prove that the morphologic pattern is truly idiopathic. The terminology used in reporting pathologic and radiologic images should clearly indicate the differential diagnosis of the morphologic pattern. Terms such as *DIP pattern* and *NSIP pattern* can be helpful in indicating that one is discussing the histologic or radiologic pattern rather than the clinical syndrome. This convention will be used throughout this review. While each pattern is pathologically distinct, two or more patterns may be present in a single biopsy specimen, which can sometimes lead to diagnostic difficulty (eg, NSIP and UIP). Nonspecific terms such as *alveolitis* or *fibrosing alveolitis* should not be used.

UIP is the most common of the IIPs (5). NSIP is the next most frequent, followed by COP. DIP, RB-ILD, and AIP are less common, while LIP is rare.

Distinction among the IIPs is important largely because of the differences in prognosis associated with these conditions (5). Because UIP is associated with a sharply decreased survival, compared with that associated with the other conditions, the most important task for the radiologist and pathologist is to distinguish individuals with this morphologic pattern from those with the other entities.

USUAL INTERSTITIAL PNEUMONIA AND IDIOPATHIC PULMONARY FIBROSIS

The terms *usual interstitial pneumonia* and *idiopathic pulmonary fibrosis* have become much more narrowly defined since they were originally proposed several decades ago. The term *idiopathic pulmonary fibrosis* is now applied solely to the clinical syndrome associated with the morphologic pattern of UIP and specifically excludes entities such as NSIP and DIP (6). At histologic examination, the fibroblastic focus—a cluster of fibroblasts and immature connective tissue within the pulmonary interstitium (Fig 1)—has been recognized as a key early lesion of UIP (7). Because UIP is primarily a fibrotic condition, the concept of alveolitis as an inflammatory phase of UIP is no longer valid. The histologic diagnosis of UIP is based on temporal heterogeneity: the identification of fibrotic lesions of different stages (fibroblastic foci, mature fibrosis, and honeycombing) within the same biopsy specimen (Fig 1) (3). In addition to the temporal heterogeneity, the histologic abnormality is spatially heterogeneous, with patchy lung involvement and normal lung adjacent to severely fibrotic lung.

Patients with idiopathic pulmonary fibrosis are usually over 50 years of age at the time of presentation, with men being affected slightly more often than women (6). In most patients, symptoms have been present for more than 6 months before presentation. Patients usually present with progressive shortness of breath and nonproductive cough. Fine crackles may be found during clinical examination, and physiologic evaluation usually shows lung restriction. The clinical course of idiopathic pulmonary fibrosis is invariably one of gradual deterioration, sometimes interspersed with periods of more rapid decline. The median survival from time of diagnosis varies between 2.5 and 3.5 years (8). Idiopathic pulmonary fibrosis, as currently defined, does not usually respond to steroid treatment, in contrast to the other IIPs.

UIP is important for the radiologist because it is one of the most common interstitial lung diseases and because a confident thin-section CT diagnosis of UIP is usually correct. The radiologist must be familiar with the typical features of UIP and with the features that make UIP unlikely. UIP is characterized on thin-section CT images by the presence of reticular opacities, often associated with traction bronchiectasis (Fig 2) (9,10). Honeycombing is common. Ground-glass opacity is common but is usually less extensive than the reticular pattern. Architectural distortion, which reflects lung fibrosis, is often prominent. Lobar volume loss is seen in cases of more advanced fibrosis. The distribution of UIP on CT images is characteristically basal and peripheral, though it is often patchy. Micronodules, air trapping, nonhoneycomb cysts, extensive ground-glass opacification, consolidation, or a predominantly peribronchovascular distribution should lead to an alternative diagnosis.

The authors of several retrospective studies (11–15) have documented that the positive predictive value of a CT diagnosis of UIP ranges from 70% to 100%, while the positive predictive value of a confident CT diagnosis of UIP is 95%–100%. In a recent prospective study (16), the positive predictive value of a diagnosis of UIP was about 90%, while the positive predictive value of a confident diagnosis of UIP was 96%. It should be noted that, in general, these studies were performed by expert pulmonary radiologists. Also, in these studies a confident CT diagnosis of UIP was not made in 25%–50% of cases of histologically demonstrated UIP. A confident CT diagnosis of UIP is difficult to make in patients who do not show all of the typical features, particularly honeycombing.

Because of the high degree of accuracy of thin-section CT diagnosis in many cases of UIP, the diagnosis of UIP is commonly based on clinical and imaging features, without the need for surgical biopsy. However, some cases of UIP have a CT appearance that overlaps with that of NSIP. In such cases, the diagnosis of UIP can only be made with the aid of lung biopsy. The American Thoracic Society has published criteria for diagnosis of UIP

TABLE 1
American Thoracic Society and European Respiratory Society Classification of IIPs

Morphologic Pattern	Clinical Diagnosis
UIP	Idiopathic pulmonary fibrosis
NSIP	NSIP
DIP	DIP
Respiratory bronchiolitis	RB-ILD
Organizing pneumonia	COP
Diffuse alveolar damage	AIP
LIP	LIP

Note.—Adapted and reprinted, with permission, from reference 1.

in the absence of a surgical biopsy (Table 3) (6). Flaherty et al (17) recently suggested that the patients with histologically proved UIP who had definite or probable UIP according to thin-section CT criteria had a shorter survival than did those with indeterminate thin-section CT findings. This is most likely because the typical thin-section CT criteria for diagnosis of UIP include the presence of honeycombing and may thereby result in selection of patients with later or more severe disease. Their study reemphasizes the importance of seeking lung biopsy in patients in whom CT findings are not diagnostic of UIP.

On serial CT scans in patients with idiopathic pulmonary fibrosis, the areas of ground-glass opacity may regress, but these areas more commonly progress to fibrosis with honeycombing (Fig 2) (18,19). Honeycomb cysts usually enlarge slowly over time.

Important complications of idiopathic pulmonary fibrosis include infection, lung cancer, and accelerated deterioration (20). Since most treatments for idiopathic pulmonary fibrosis cause immunocompromise, a variety of opportunistic infectious organisms may be present in these patients, including *Pneumocystis carinii*, *Mycobacterium avium-intracellulare* complex (Fig 3), and mycetoma due to *Aspergillus* species or other organisms. The reported frequency of lung cancer in

TABLE 2
IIP Patterns

Morphologic Pattern	Histologic Features	Imaging Features	Imaging Differential Diagnosis
UIP	Spatial and temporal heterogeneity, dense fibrosis, fibroblastic foci, honeycombing	Basal, peripheral predominance, often patchy, reticular abnormality, honeycombing	Collagen vascular disease, asbestosis, chronic hypersensitivity pneumonitis
NSIP	Spatially and temporally homogeneous lung fibrosis or inflammation	Basal predominance, ground-glass abnormality, reticular abnormality	Collagen vascular disease, chronic hypersensitivity pneumonitis, DIP
DIP	Diffuse macrophage accumulation in alveoli	Basal, peripheral predominance; ground-glass attenuation; sometimes cysts	Hypersensitivity pneumonitis, NSIP
Respiratory bronchiolitis	Peribronchiolar macrophage accumulation, bronchiolar fibrosis; macrophages have dusty brown cytoplasm	Centrilobular nodules, ground-glass attenuation	Hypersensitivity pneumonitis
Organizing pneumonia	Patchy distribution of intraluminal organizing fibrosis in distal airspaces; preservation of lung architecture; uniform temporal appearance; mild interstitial chronic inflammation	Ground-glass attenuation; consolidation basal, peripheral predominance	Collagen vascular disease, infection, vasculitis, sarcoidosis, lymphoma, alveolar carcinoma
Diffuse alveolar damage	Diffuse distribution, uniform temporal appearance, alveolar septal thickening due to organizing fibrosis, airspace organization, hyaline membranes	Diffuse, ground-glass attenuation, consolidation	Acute respiratory distress syndrome, infection, hydrostatic edema, hemorrhage
LIP	Diffuse lymphoplasmacytic infiltration of alveolar septa	Ground-glass attenuation, cysts	DIP, NSIP, hypersensitivity pneumonitis

Source.—Reference 4.

TABLE 3
American Thoracic Society Criteria for Diagnosis of IPF in Absence of Surgical Biopsy

Criterion Type	Criterion Definition*
Major†	Exclusion of other known causes of interstitial lung disease (eg, certain drug toxicities, environmental exposures, connective tissue disease)
	Abnormal pulmonary function studies that include evidence of restriction (reduced vital capacity often with increased FEV_1/FVC) and impaired gas exchange (increased $P(A-a)O_2$ with rest or exercise or decreased DLCO)
	Bibasilar reticular abnormalities with minimal ground-glass opacities at thin-section CT
	Transbronchial lung biopsy or bronchoalveolar lavage specimens that show no features supporting alternate diagnosis
Minor‡	Age > 50 y
	Insidious onset of otherwise unexplained dyspnea on exertion
	Illness duration > 3 mo
	Bibasilar, inspiratory crackles (dry or "Velcro"-type in quality

Source.—Reference 15.
* DLCO = diffusing capacity of carbon monoxide, FEV_1 = forced expiratory volume in 1 second, FVC = forced vital capacity, $P(A-a)O_2$ = alveolar-arterial oxygen pressure difference.
† All must be present.
‡ Three of four must be present.

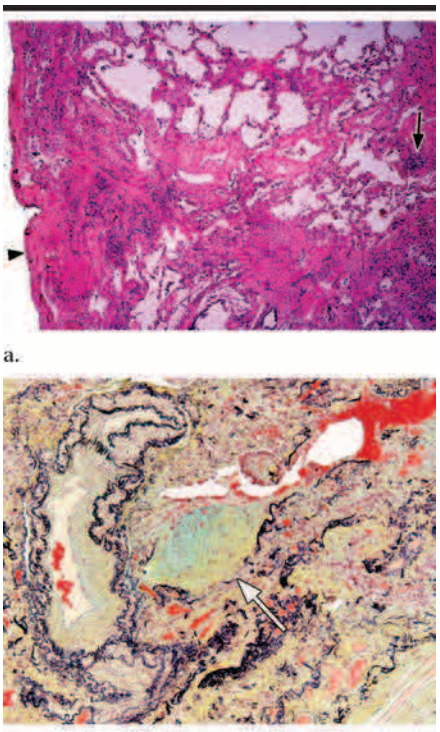

a.

b.

Figure 1. Photomicrographs show UIP pattern. **(a)** Patchy fibrosis with lung remodeling architecture and striking subpleural distribution. Interstitial chronic inflammation is mild, with a few lymphoid aggregates (arrow). Areas of normal lung are present. There are no features of other interstitial lung disorders. Arrowhead = pleura. (Hematoxylin-eosin stain; original magnification, ×4.) **(b)** Fibroblastic focus of loose organizing connective tissue (arrow) is seen adjacent to a dense collagenous scar. (Movat stain; original magnification, ×10.)

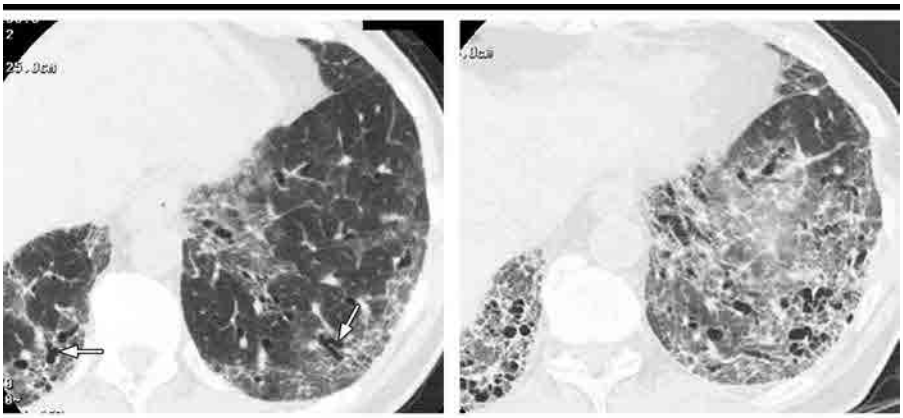

a. b.

Figure 2. Transverse CT images in a 65-year-old man with progressive shortness of breath due to UIP. **(a)** Left lower lobe shows peripheral ground-glass opacity and reticular patterns with traction bronchiectasis (arrows). **(b)** Two years later, ground-glass opacification has progressed to reticular pattern and honeycombing, with progression of traction bronchiectasis.

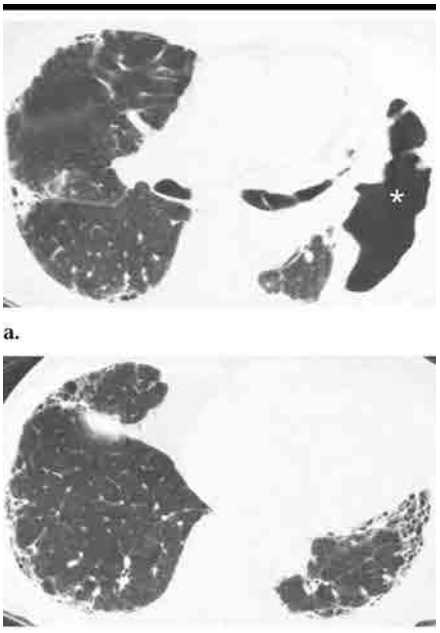

a.

b.

Figure 3. Transverse CT images in a 78-year-old man with UIP complicated by infection with *M avium-intracellulare* complex. **(a, b)** Predominantly basal subpleural reticular pattern is present, with large left upper lobe cavity (*).

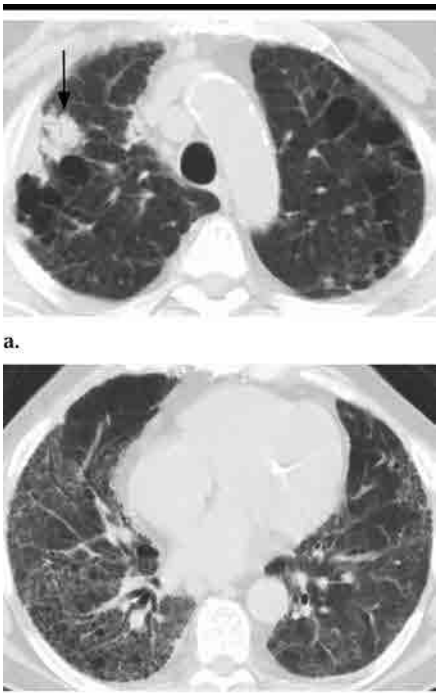

a.

b.

Figure 4. Transverse thin-section CT images in a 72-year-old man with UIP complicated by large cell neuroendocrine lung cancer, which was detected incidentally on chest radiograph (not shown). **(a, b)** Subpleural mass in right upper lobe (arrow) is evident at two levels, with extensive, predominantly basal honeycombing.

idiopathic pulmonary fibrosis varies widely from series to series but is probably about 10%–15% (21). When cancer occurs, it seems to predominantly affect the lower lobes (Fig 4).

Accelerated deterioration ("acute exacerbation") of idiopathic pulmonary fibrosis (22) manifests with a relatively short onset of progressive dyspnea or cough, occasionally associated with systemic symptoms, in a patient with underlying idiopathic pulmonary fibrosis. There is usually a short prodrome of 4–8 weeks duration. On CT images, the accelerated deterioration is characterized by diffuse or peripheral ground-glass opacification (Fig 5) (22), which must be distinguished clinically from opportunistic viral or *Pneumocystis* infection.

The differential diagnosis for the CT pattern of UIP includes collagen vascular disease, chronic hypersensitivity pneumonitis, and asbestosis (Fig 6). Features that help to distinguish chronic hypersensitivity pneumonitis from idiopathic pulmonary fibrosis include upper or middle zone predominance, presence of micronodules, absence of honeycombing (23), and presence of mosaic attenuation or air trapping (24). However, there are a minority of cases of chronic hypersensitivity pneumonitis with predominantly basal reticular pattern and honeycombing, which are radiologically indistinguishable from UIP.

NONSPECIFIC INTERSTITIAL PNEUMONIA

NSIP is a histologic entity characterized by spatially homogenous alveolar wall thickening caused by inflammation and/

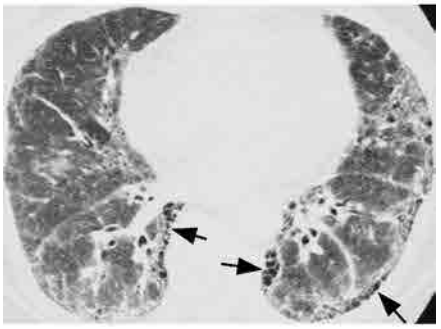

a.

b.

Figure 5. Transverse CT images of accelerated UIP in a 78-year-old man with rapidly progressive shortness of breath. **(a)** Baseline image shows subpleural reticular pattern and honeycombing (arrows), with ground-glass opacity in remainder of the lung. **(b)** Five months later, after 4 weeks of progressive breathlessness, progression of honeycombing and extensive new ground-glass opacification are shown. Biopsy specimen showed organizing pneumonia pattern superimposed on background UIP. Patient responded to aggressive immunosuppressive treatment.

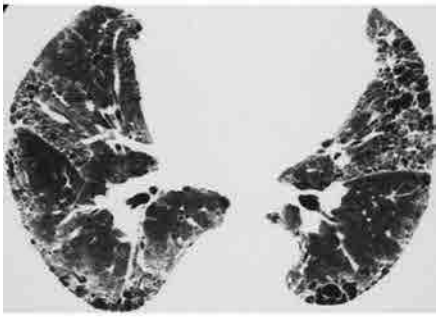

a.

b.

Figure 6. UIP pattern in a 59-year-old man with asbestosis. **(a)** Transverse thin-section CT image shows predominantly peripheral honeycombing associated with reticular pattern and a lesser proportion of ground-glass opacification. **(b)** Transverse CT image (mediastinal window) shows bilateral noncalcified pleural plaques (arrows).

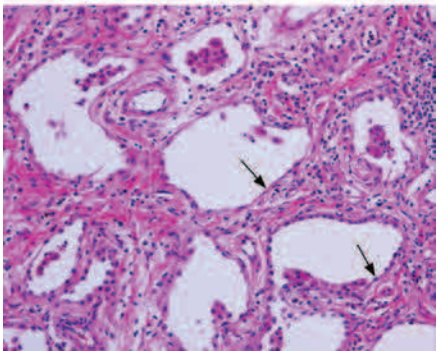

Figure 7. Photomicrograph shows NSIP with fibrosing pattern. Alveolar walls (arrows) show diffuse thickening caused by fibrosis and mild interstitial inflammation. No fibroblastic foci are present. (Hematoxylin-eosin stain; original magnification, ×10.)

or fibrosis (25). The spatial and temporal homogeneity of this pattern are important in distinguishing NSIP from UIP (Figs 7, 8). The most important clinical fact about NSIP is that the prognosis is substantially better than that of UIP (5,17,26) (Fig 9). NSIP may be classified on the basis of the relative amounts of lung fibrosis and inflammation. Patients with predominant fibrosis (fibrotic NSIP) (Fig 7) have a poorer prognosis than do those with inflammatory histologic findings (cellular NSIP) (Fig 8) (26). The clinical features of NSIP are similar to those of UIP, except that patients with NSIP are more commonly female and generally have a younger mean age than do those with UIP.

Because of the histologic spatial homogeneity of NSIP, ground-glass opacity is its salient CT feature and is often associated with evidence of fibrosis (lobar volume loss, reticular pattern, and/or traction bronchiectasis) (Fig 10) (10,27–31). As with UIP, DIP, and COP, the abnormality usually shows a basal predominance. The transverse distribution may be subpleural, peribronchovascular, or both. Consolidation is uncommon, and honeycombing is rare. Variation among CT features of NSIP reported in existing series may be related to differences in histologic diagnostic criteria for NSIP at different centers. The CT features of cellular and fibrotic NSIP overlap considerably (32) (Fig 11).

The parenchymal abnormalities of NSIP, including reticular pattern, traction bronchiectasis, and ground-glass opacity, may all be reversible at follow-up examination (Fig 12) (31). Indeed, it seems likely that many of the patients included in previous series of fibrosing alveolitis who had a predominant pattern of ground-glass opacity had NSIP rather than UIP, which would thereby explain the fact that these patients were more likely to respond to steroid treatment (33,34).

Histologic and radiologic evidence of the NSIP pattern is commonly found in patients with collagen vascular diseases (Fig 13), hypersensitivity pneumonitis (Fig 14), and drug-induced lung disease. Therefore, the recognition of this pattern should prompt a search for the underlying cause. The CT pattern of NSIP may overlap with those of organizing pneumonia and DIP. Because the thin-section CT features of NSIP may overlap with those of organizing pneumonia, DIP, and UIP, a surgical lung biopsy should be considered when the thin-section CT pattern suggests NSIP.

DESQUAMATIVE INTERSTITIAL PNEUMONIA

DIP is an uncommon condition that primarily affects cigarette smokers in their 4th or 5th decades of life (35). It is characterized histologically by spatially homogeneous thickening of alveolar septa, associated with intraalveolar accumulation of macrophages (Fig 15). The term *desquamative* was applied to this entity because the intraalveolar macrophages were initially thought to represent desquamated alveolar cells.

DIP is more common in men than in women (male-to-female ratio, 2:1). A progressive onset of dyspnea and dry cough is usual, and patients may progress to respiratory failure. Digital clubbing develops in about 40% of cases. Most patients improve with smoking cessation and oral corticosteroids. The overall survival is about 70% after 10 years.

Ground-glass opacification, present on CT images in all cases of DIP (Fig 16) (10,36), is due to the spatially homogeneous accumulation of intraalveolar macrophages and alveolar septal thickening. The abnormality has a lower-zone

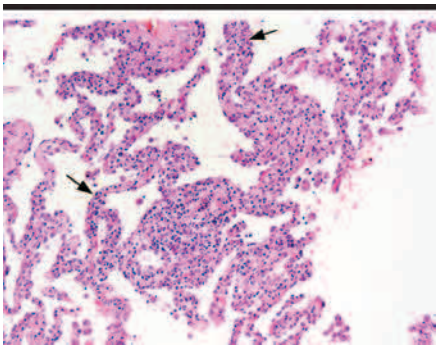

Figure 8. Photomicrograph shows NSIP with cellular pattern. Alveolar walls (arrows) are infiltrated by a moderate chronic inflammatory infiltrate. (Hematoxylin-eosin stain; original magnification, ×10.)

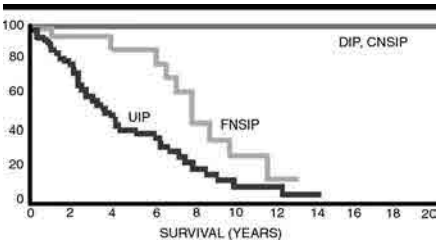

Figure 9. Kaplan-Meier survival curves for patients with idiopathic DIP or cellular NSIP *(CNSIP)*, fibrotic NSIP *(FNSIP)*, and UIP. Patients with idiopathic DIP and cellular NSIP have excellent survival, those with idiopathic UIP have the worst survival, and those with idiopathic fibrosing NSIP have an intermediate survival ($P < .001$). (Reprinted, with permission, from reference 26.)

Figure 11. Cellular NSIP in a 50-year-old woman with shortness of breath. Transverse CT image through lower lungs shows predominantly peribronchovascular ground-glass opacity with associated reticular pattern.

and peripheral distribution in the majority of cases. Irregular linear opacities and a reticular pattern are frequent but are limited in extent and are usually confined to the lung bases. Honeycombing is uncommon, but well-defined cysts may occur within the areas of ground-glass opacification (Fig 16). The cysts are usually round, thin-walled, and less than 2 cm in diameter (37). The ground-glass opacification usually regresses with treatment. Progression of ground-glass opacification to a reticular pattern occurs infrequently (<20% of cases).

DIP, respiratory bronchiolitis, and RB-ILD are considered to be part of a spectrum of smoking-related lung diseases (38), but they differ histologically in that DIP is diffuse while respiratory bronchiolitis and RB-ILD are centered on the respiratory bronchiole. On CT images, RB-ILD differs from DIP in that the ground-glass opacification of RB-ILD is usually less extensive, more patchy, and more poorly defined than that in DIP. Centrilobular nodules are uncommon in DIP. The changes of respiratory bronchiolitis are usually less severe than those of RB-ILD.

Conditions that may be radiologically indistinguishable from DIP include NSIP, acute or subacute hypersensitivity pneumonitis, and infections such as *P carinii* pneumonia.

RESPIRATORY BRONCHIOLITIS AND RB-ILD

Respiratory bronchiolitis is a histopathologic lesion found in cigarette smokers and is characterized by the presence of pigmented intraluminal macrophages within first- and second-order respiratory bronchioles (Fig 17). It is usually asymptomatic. In rare cases, however, patients who are heavy smokers may develop RB-ILD, a condition characterized by substantial pulmonary symptoms, abnormal pulmonary function, and imaging abnormalities, with respiratory bronchiolitis being the only histologic lesion identified when lung biopsy is performed. Respiratory bronchiolitis, RB-ILD, and DIP are best regarded as a part of a continuum of smoking-related lung injuries (Table 4) (38). RB-ILD usually affects heavy smokers with an average exposure of more than 30 pack-years.

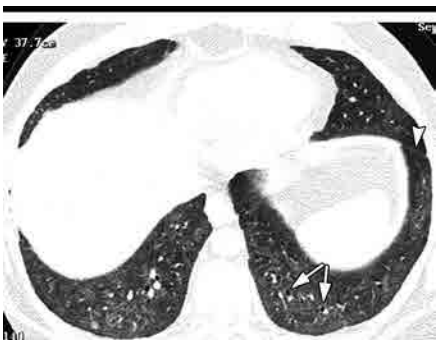

Figure 10. Fibrotic NSIP in a 54-year-old man with shortness of breath. Transverse CT image through lower lungs shows ground-glass opacity associated with traction bronchiectasis (arrows). The left major fissure is displaced posteriorly (arrowhead), indicating lobar volume loss.

Patients with asymptomatic respiratory bronchiolitis generally show mild centrilobular nodularity and small patches of ground-glass opacity (Fig 18) (39). In RB-ILD, both of these findings, particularly that of ground-glass opacity, become more extensive (Fig 19) (40). The CT findings of RB-ILD are at least partially reversible in patients who stop smoking (41).

The CT features of RB-ILD may be similar to those of hypersensitivity pneumonitis and NSIP. The clinical differentiation of RB-ILD from hypersensitivity pneumonitis is facilitated by exposure history and by the fact that most patients with hypersensitivity pneumonitis are nonsmokers (42,43).

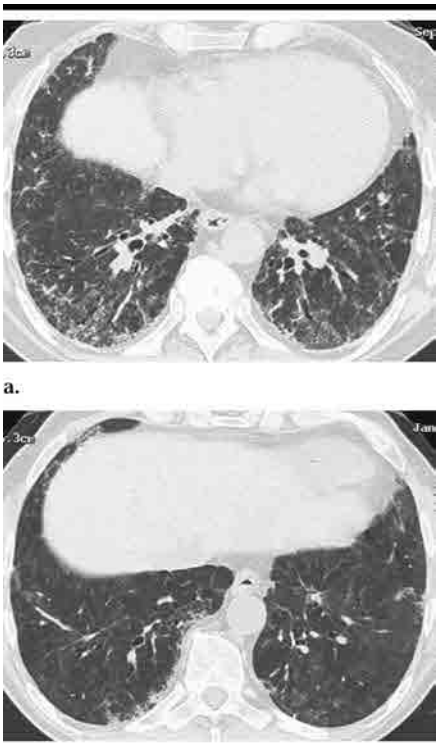

a.

b.

Figure 12. Reversibility of reticular pattern and traction bronchiectasis in a 58-year-old man with NSIP (mixed cellular and fibrotic pattern). **(a)** Initial transverse CT image shows marked basal reticular pattern with traction bronchiectasis. **(b)** At follow-up transverse CT performed 2 years later (without specific treatment), image obtained at a slightly lower level shows substantial resolution of reticular pattern, with residual ground-glass opacity.

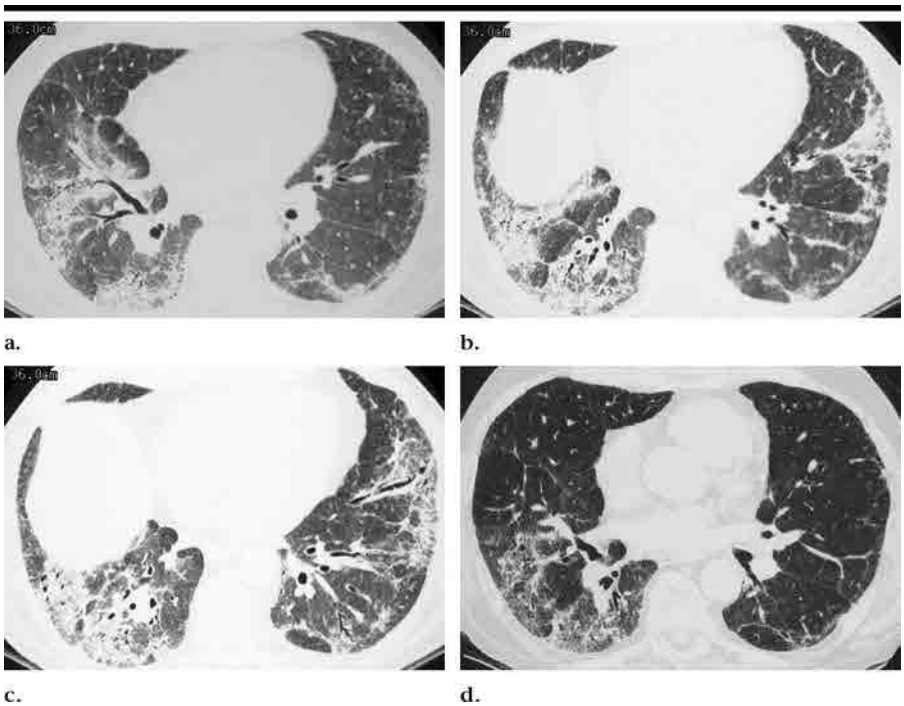

Figure 13. NSIP in a 62-year-old man with scleroderma. **(a–c)** Transverse thin-section CT images show peribronchovascular and peripheral distribution of ground-glass opacity associated with reticular pattern. Marked bilateral lower-lobe volume loss and traction bronchiectasis indicate extensive lung fibrosis. **(d)** Transverse thin-section CT image obtained 2 years later shows decreased ground-glass opacification but persistent reticular pattern.

Figure 16. Transverse CT image in a 62-year-old man with DIP who presented with shortness of breath. Predominantly basal ground-glass opacification is seen with multiple peribronchovascular cysts (arrows).

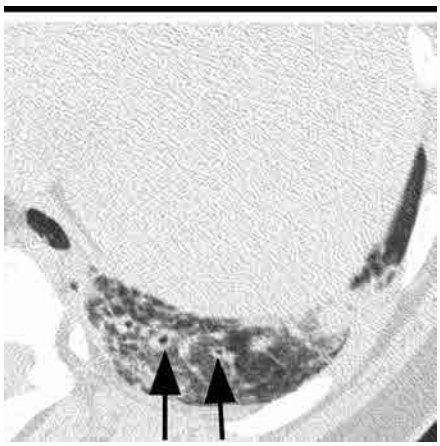

Figure 14. NSIP pattern in a 62-year-old woman with hypersensitivity pneumonitis. Transverse thin-section CT image through left lower lung shows ground-glass opacity associated with traction bronchiectasis (arrows). Histologic analysis showed NSIP pattern, with granulomas consistent with hypersensitivity pneumonitis.

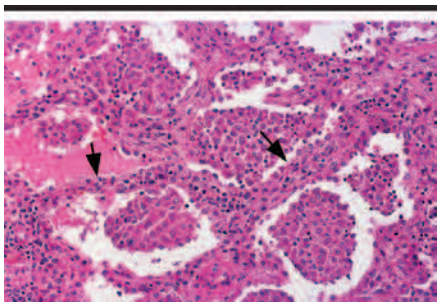

Figure 15. Photomicrograph shows DIP pattern. Alveolar spaces are diffusely involved by marked alveolar macrophage accumulation, and there is mild interstitial thickening caused by fibrous connective tissue (arrows). (Hematoxylin-eosin stain; original magnification, ×10.)

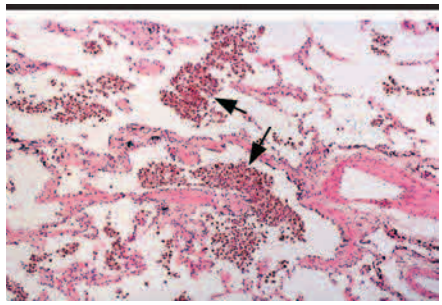

Figure 17. Photomicrograph shows respiratory bronchiolitis. Faintly pigmented alveolar macrophages (arrows) fill the lumen of this respiratory bronchiole and surrounding airspaces. There is mild thickening of the respiratory bronchiole wall. (Hematoxylin-eosin stain; original magnification, ×4.)

CRYPTOGENIC ORGANIZING PNEUMONIA

COP has also been called bronchiolitis obliterans organizing pneumonia (BOOP) or idiopathic BOOP. The term *cryptogenic organizing pneumonia* is preferred because its clinical, physiologic, and imaging features are unrelated to bronchiolar obliteration. For these reasons, COP is more appropriately classified as an IIP than as a small-airways disease. Although the organizing pneumonia process is primarily intraalveolar, it was included in the classification of the interstitial pneumonias because of its idiopathic nature and because its appearance may overlap with that of the other interstitial pneumonias. As with the other idiopathic pneumonias, the term *organizing pneumonia* is used to refer to the morphologic pattern (which may occur in a wide variety of entities), while COP is used to indicate the associated idiopathic clinical syndrome.

Histologically, organizing pneumonia is distinguished by patchy areas of consolidation characterized by polypoid plugs of loose organizing connective tissue with or without endobronchiolar intraluminal polyps (Fig 20). The architecture of the lung is preserved, and all the connective tissue is the same age. Inflammation is mild or moderate.

Patients with COP typically present with cough and dyspnea of relatively short duration. Because of the presence of consolidation on chest radiographs,

Figure 18. Respiratory bronchiolitis in a 34-year-old male cigarette smoker. Transverse thin-section CT image obtained with patient in prone position shows small patch of focal ground-glass opacity (arrowhead) in posterior portion of right lung and some centrilobular nodules (arrows).

TABLE 4
Continuum of Smoking-related Lung Diseases

Condition	Symptoms and Physiologic Impairment	Pathologic Feature	CT Feature: Ground-Glass Opacification	CT Feature: Centrilobular Nodules
RB*	Uncommon	Bronchiolocentric	Small patches	Mild
RB-ILD	Severe	Macrophages extend into peribronchioloar region	Extensive	Extensive
DIP	Severe	Diffuse intraalveolar macrophages	Extensive	Uncommon

* RB = respiratory bronchiolitis.

Figure 19. RB-ILD in a 41-year-old man with 30 pack-year history of cigarette smoking. Transverse CT image shows widespread ground-glass opacification, with some poorly defined centrilobular nodules (arrowheads).

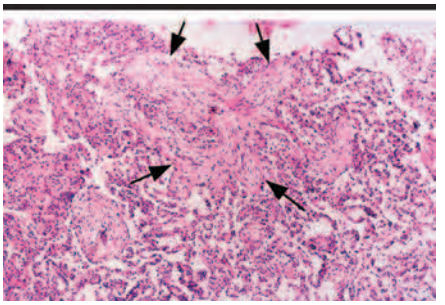

Figure 20. Photomicrograph shows organizing pneumonia pattern. Loose plugs of connective tissue (arrows) are present in an alveolar duct and adjacent alveolar spaces. Lung architecture is preserved, and connective tissue is all the same age. (Hematoxylin-eosin stain; original magnification, ×10.)

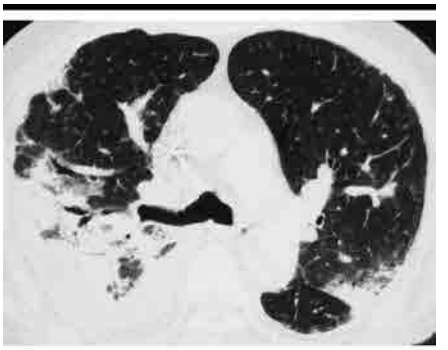

a.

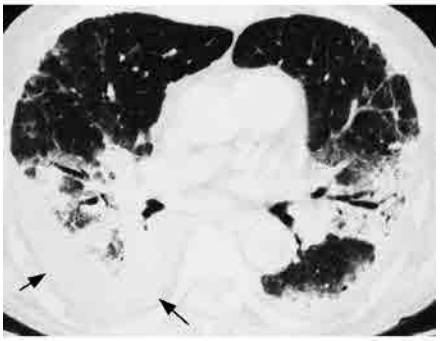

b.

Figure 21. COP in a 75-year-old man who presented with recurrent "pneumonia." **(a, b)** Transverse CT images show bilateral pulmonary consolidation with subpleural and peribronchovascular predominance and right pleural effusion (arrows).

the initial diagnosis often is pneumonia, but the patients fail to respond to treatment with antibiotics.

COP is characterized radiographically by unilateral or bilateral areas of consolidation (44). Consolidation is present on CT images in 90% of patients with COP (Fig 20), with a subpleural or peribronchial distribution in up to 50% of cases (45). The lower lungs are more frequently involved. Air bronchograms, with mild cylindric bronchial dilatation, are common. Ground-glass opacities are present in about 60% of cases. Reticular opacities are less common but, when present, are associated with histologic evidence of fibrosis (46). Pleural effusion may occur, although this is relatively uncommon (Fig 21).

Most patients with COP demonstrate radiologic improvement or resolution with steroid treatment. The parenchymal abnormalities may spontaneously resolve or migrate. If reticular opacities are present on the chest radiograph or CT image of a patient with COP, the patient is less likely to respond to steroids (47,48).

In addition to cases of COP, the organizing pneumonia pattern may be found in cases of collagen vascular diseases (particularly rheumatoid arthritis and polymyositis) (Fig 22). The differential diagnosis of COP includes bronchioloalveolar carcinoma, lymphoma, vasculitis, sarcoidosis, chronic eosinophilic pneumonia, and infection. Most of these entities can be excluded with the aid of clinical evaluation, bronchoalveolar lavage, and/or transbronchial biopsy.

ACUTE INTERSTITIAL PNEUMONIA

AIP is a rapidly progressive form of interstitial pneumonia. The histologic findings are those of diffuse alveolar damage (Fig 23) indistinguishable from the histologic pattern found in acute respiratory distress syndrome caused by sepsis and shock. Edema and hyaline membranes are prominent in the acute phase, and organizing alveolar septal fibrosis and pneumocyte hyperplasia are conspicuous in the organizing phase. The term *acute interstitial pneumonia* is reserved for diffuse alveolar damage of unknown origin.

Patients with AIP often have a prior illness suggestive of a viral upper respiratory infection with constitutional symp-

Figure 22. Organizing pneumonia pattern in a 55-year-old woman with rheumatoid arthritis. Transverse CT image shows focal consolidation (arrows) in lingula, with an air bronchogram. The abnormality was not associated with symptoms of infection and resolved spontaneously.

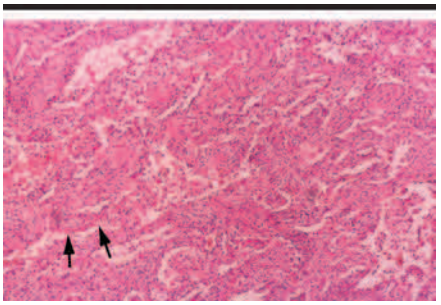

Figure 23. Photomicrograph shows diffuse alveolar damage. Lung shows diffuse alveolar wall thickening caused by proliferating connective tissue and prominent hyaline membranes (arrows). (Hematoxylin-eosin stain; original magnification, ×20.)

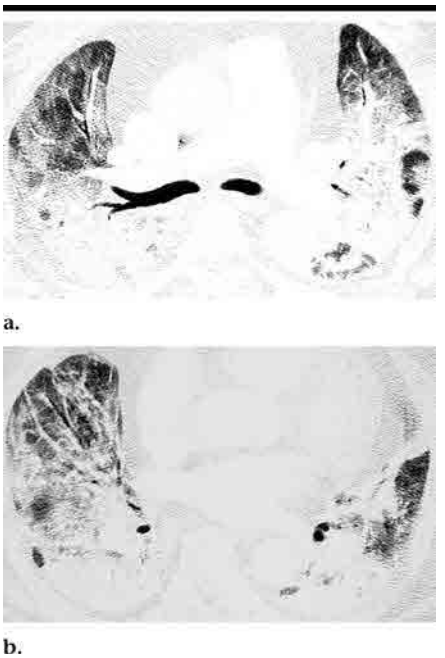

a.

b.

Figure 24. AIP in a 65-year-old woman who presented with rapidly progressive shortness of breath. **(a, b)** Transverse CT images show extensive ground-glass opacity, with consolidation in more dependent parts of the lung and lobular areas of sparing.

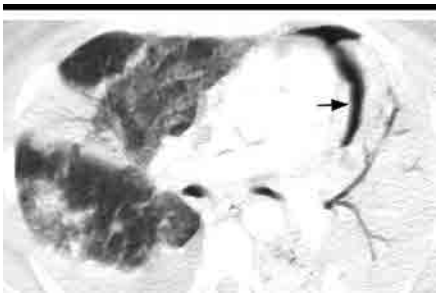

Figure 25. Acute respiratory distress syndrome secondary to trauma in a 50-year-old woman. Transverse CT image shows patchy geographic lung consolidation on the right with more diffuse consolidation in the left upper lung. A small left pneumothorax (arrow) is present.

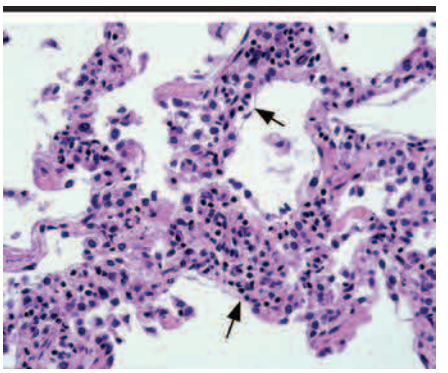

Figure 26. Photomicrograph shows LIP. Alveolar walls (arrows) are markedly infiltrated by lymphocytes and plasma cells. (Hematoxylin-eosin stain; original magnification, ×20.)

toms. Hypoxemia progresses rapidly to respiratory failure. Mechanical ventilation is usually required. Most patients fulfill the clinical criteria for acute respiratory distress syndrome: acute onset, ratio of arterial partial pressure of oxygen to fraction of inspired oxygen of 200 mm Hg or lower, diffuse bilateral opacities on chest radiographs, and pulmonary capillary wedge pressure of less than 18 mm Hg. The mortality rate is 50% or higher.

The most common CT findings in patients with AIP are areas of ground-glass opacity, bronchial dilatation, and architectural distortion (Fig 24) (49). In the early exudative phase, the lung shows areas of ground-glass opacity that are most often bilateral and patchy, with areas of focal sparing of lung lobules, that produce a geographic appearance (50). Consolidation is seen in most cases, particularly in the dependent lung. The organizing stage of diffuse alveolar damage is associated with distortion of bronchovascular bundles and traction bronchiectasis. The few patients who survive show progressive clearing of the ground-glass opacity and consolidation. The most common residual thin-section CT findings are areas of hypoattenuation, lung cysts, reticular pattern, and associated parenchymal distortion occurring mainly in the nondependent lung (51).

Although the radiologic appearances of AIP and acute respiratory distress syndrome overlap, patients with AIP are more likely to have a symmetric lower-lobe distribution of abnormalities and a greater prevalence of honeycombing (52). The reason for the increased prevalence of honeycombing is unclear but may be related to the presence of underlying UIP in some cases. In addition to acute respiratory distress syndrome (Fig 25), the radiologic differential diagnosis of AIP depends on the stage but can include widespread infection, hydrostatic edema, acute eosinophilic pneumonia, and pulmonary hemorrhage.

LYMPHOID INTERSTITIAL PNEUMONIA

Liebow and Carrington (53) introduced the term *lymphoid interstitial pneumonia* in 1973 to describe a diffuse lymphocytic interstitial infiltrate that was distinct from other patterns of interstitial pneumonia (Fig 26). The alveolar septal interstitium is infiltrated by lymphocytes and small to moderate numbers of plasma cells. Immunohistochemical analysis is important for distinguishing LIP from low-grade lymphoma. If LIP is proved to be due to polyclonal lymphocyte proliferation, progression to lymphoma is quite uncommon. LIP is commonly associated with connective tissue disorders (particularly Sjögren syndrome), with immunodeficiency (particularly acquired immunodeficiency syndrome), and with Castleman syndrome. Idiopathic LIP is rare, but it was included in the American Thoracic Society and European Respiratory Society classification because it must be considered in the clinical and radiologic differential diagnosis of diffuse lung disease, and its histologic pattern is unequivocally that of an interstitial pneumonia. The clinical manifestation of LIP

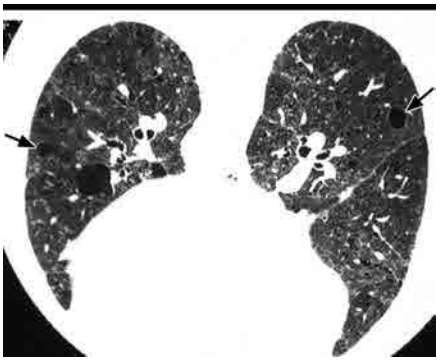

Figure 27. LIP caused by Sjögren syndrome in a 62-year-old woman. Transverse thin-section CT image obtained with patient prone shows diffuse ground-glass opacification and multiple lung cysts (arrows).

- Each IIP pattern seen at histologic or CT examination is linked to a specific clinical syndrome
- Classification of IIP is based on histologic criteria, but each histologic pattern is associated with a characteristic imaging pattern that correlates well with histologic findings
- Differential diagnosis of IIPs always includes underlying collagen vascular disease and inhalation exposures
- Nonspecific terms such as *alveolitis* or *fibrosing alveolitis* should not be used
- Typical CT features of each IIP are distinct, although with some overlap
- CT features of UIP are often diagnostic
- CT features of organizing pneumonia may be diagnostic in correct clinical context
- CT features of NSIP, DIP, RB-ILD and LIP are less specific
- CT features of AIP are similar to those of ARDS from other causes
- Radiologist must distinguish patients with typical features of UIP, who will usually not require biopsy, from those with other lung diseases, who may require biopsy.
- Clinical evaluation must prove that an interstitial pneumonia is idiopathic and exclude a recognizable cause (eg, collagen vascular disease)

Figure 28. American Thoracic Society and European Respiratory Society classification of IIPs: key points for the radiologist. *ARDS* = acute respiratory distress syndrome.

is usually that of the underlying systemic disease.

The dominant CT finding in LIP is usually ground-glass opacity (Fig 27). Perivascular cysts or, less commonly, perivascular honeycombing can also be seen (54,55). Reticular pattern is seen in about half of patients. Lung nodules and widespread consolidation may occur. Other findings may include thickening of the bronchovascular bundles and interlobular septal thickening.

ACCURACY OF CT DIAGNOSIS OF IIP

As discussed earlier in this review, the accuracy of CT diagnosis of IIPs is greatest for UIP. The classic CT features of COP (subpleural or peribronchovascular consolidation) can be diagnostic if infection, malignancy, and eosinophilic pneumonia are excluded.

Ground-glass opacity, with or without reticular pattern, is the salient feature of NSIP, DIP, RB-ILD, and LIP. Apart from the presence of cysts in some cases of DIP and LIP, there are no firm criteria for distinguishing among these entities. Although the prognosis of these non-UIP diseases is similar, histologic evaluation is often important to help exclude other causes of diffuse ground-glass opacity such as hypersensitivity pneumonitis.

Because AIP usually manifests as acute hypoxemic respiratory failure, it does not enter into the clinical differential diagnosis of the other IIPs.

Johkoh et al (10) reviewed the accuracy of CT diagnosis in 129 patients with UIP, NSIP, DIP, COP, or AIP. They found that the positive predictive value of CT for diagnosis of each entity was 79% for COP, 71% for UIP, 65% for AIP, 63% for DIP, and only 9% for NSIP. The low level of accuracy for diagnosis of NSIP may be due to the fact that the CT features of NSIP were not well established at the time the study was performed. Their study may have included a relatively large number of cases of atypical UIP, since patients with typical UIP are usually treated without surgical biopsy. A more recent study (32) in patients with UIP and NSIP found that the positive predictive value of a diagnosis of NSIP was 67%. In about 25% of cases of UIP, however, the CT appearances overlap with those of NSIP. Since the prognosis of NSIP is substantially different from that of UIP, biopsy may be necessary to distinguish these cases of "atypical UIP" from NSIP.

INTEGRATED DIAGNOSIS OF IIP

Distinction among the IIPs is important largely because of the differences in prognosis associated with these conditions (5). Because UIP is associated with sharply decreased survival relative to that of the other conditions, the most important task for the radiologist and pathologist is to distinguish individuals with this morphologic pattern from those with the other entities.

The diagnosis of IIP requires integration of the morphologic patterns identified by the radiologist and pathologist with the clinical features evaluated by the clinician. A critical role for the clinician is to determine whether the interstitial abnormality is idiopathic or related to an inhalational exposure or to collagen vascular disease. The radiologist must determine whether the CT features are typical for UIP or for organizing pneumonia or whether the features are less specific. The decision about biopsy in the patient suspected of having an IIP should be based on consultation between the clinician and radiologist. Patients with typical clinical and radiologic features of UIP will usually not need to undergo biopsy. Patients with typical clinical and radiologic features of organizing pneumonia may not require a biopsy if infection and neoplasm can be excluded after bronchoscopy with lavage and biopsy. The other interstitial pneumonias usually cannot be distinguished on the basis of clinical and CT features, and thoracoscopic biopsy will usually be necessary if a precise histologic diagnosis is required—particularly if hypersensitivity pneumonitis is included in the differential diagnosis (unless the exposure history provides compelling evidence for hy-

persensitivity pneumonitis). When surgical biopsy is performed, the results should always be interpreted in conjunction with the CT findings, since CT shows the macroscopic morphology of the entire lung while biopsy reveals microscopic morphology in only one or two small peripheral areas. CT may also be helpful in identifying a suitable location for surgical biopsy.

SUMMARY

Figure 28 summarizes key points of the American Thoracic Society and European Respiratory Society classification of IIPs that are of relevance to radiologists. The IIPs are each associated with typical histologic and imaging patterns, and accurate diagnosis of these disorders requires a dynamic integrated approach correlating clinical, radiologic, and pathologic features. The CT appearances of UIP and COP may be diagnostic in the correct clinical context, but there is substantial overlap in the CT appearances of the other IIPs. The presence of cysts should suggest the possibility of LIP or DIP.

References

1. American Thoracic Society, European Respiratory Society. American Thoracic Society/European Respiratory Society International Multidisciplinary Consensus Classification of the Idiopathic Interstitial Pneumonias: this joint statement of the American Thoracic Society (ATS), and the European Respiratory Society (ERS) was adopted by the ATS board of directors, June 2001 and by the ERS executive committee, June 2001. Am J Respir Crit Care Med 2002; 165:277–304.
2. Liebow A. Definition and classification of interstitial pneumonias in human pathology. Prog Respir Res 1975; 8:1–33.
3. Katzenstein AL, Myers JL. Idiopathic pulmonary fibrosis: clinical relevance of pathologic classification. Am J Respir Crit Care Med 1998; 157:1301–1315.
4. Muller NL, Colby TV. Idiopathic interstitial pneumonias: high-resolution CT and histologic findings. RadioGraphics 1997; 17:1016–1022.
5. Collard HR, King TE Jr. Demystifying idiopathic interstitial pneumonia. Arch Intern Med 2003; 163:17–29.
6. American Thoracic Society. Idiopathic pulmonary fibrosis: diagnosis and treatment—international consensus statement: American Thoracic Society (ATS), and the European Respiratory Society (ERS). Am J Respir Crit Care Med 2000; 161:646–664.
7. King TE Jr, Schwarz MI, Brown K, et al. Idiopathic pulmonary fibrosis: relationship between histopathologic features and mortality. Am J Respir Crit Care Med 2001; 164:1025–1032.
8. Bjoraker J, Ryu J, Edwin M, et al. Prognostic significance of histopathologic subsets in idiopathic pulmonary fibrosis. Am J Respir Crit Care Med 1998; 157:199–203.
9. Nishimura K, Kitaichi M, Izumi T, Nagai S, Kanaoka M, Itoh H. Usual interstitial pneumonia: histologic correlation with high-resolution CT. Radiology 1992; 182:337–342.
10. Johkoh T, Muller NL, Cartier Y, et al. Idiopathic interstitial pneumonias: diagnostic accuracy of thin-section CT in 129 patients. Radiology 1999; 211:555–560.
11. Grenier P, Valeyre D, Cluzel P, Brauner MW, Lenoir S, Chastand C. Chronic diffuse interstitial lung disease: diagnostic value of chest radiography and high-resolution CT. Radiology 1991; 179:123–132.
12. Mathieson JR, Mayo JR, Staples CA, Muller NL. Chronic diffuse infiltrative lung disease: comparison of diagnostic accuracy of CT and chest radiography. Radiology 1989; 171:111–116.
13. Tung KT, Wells AU, Rubens MB, Kirk JM, du Bois RM, Hansell DM. Accuracy of the typical computed tomographic appearances of fibrosing alveolitis. Thorax 1993; 48:334–338.
14. Lee KS, Primack SL, Staples CA, Mayo JR, Aldrich JE, Muller NL. Chronic infiltrative lung disease: comparison of diagnostic accuracies of radiography and low- and conventional-dose thin-section CT. Radiology 1994; 191:669–673.
15. Swensen S, Aughenbaugh G, Myers J. Diffuse lung disease: diagnostic accuracy of CT in patients undergoing surgical biopsy of the lung. Radiology 1997; 205:229–234.
16. Hunninghake GW, Zimmerman MB, Schwartz DA, et al. Utility of a lung biopsy for the diagnosis of idiopathic pulmonary fibrosis. Am J Respir Crit Care Med 2001; 164:193–196.
17. Flaherty KR, Thwaite EL, Kazerooni EA, et al. Radiological versus histological diagnosis in UIP and NSIP: survival implications. Thorax 2003; 58:143–148.
18. Akira M, Sakatani M, Ueda E. Idiopathic pulmonary fibrosis: progression of honeycombing at thin-section CT. Radiology 1993; 189:687–691.
19. Terriff B, Kwan S, Chan-Yeung M, Muller N. Fibrosing alveolitis: chest radiography and CT as predictors of clinical and functional impairment at follow-up in 26 patients. Radiology 1992; 184:445–449.
20. Panos RJ, Mortenson RL, Niccoli SA, King TJ. Clinical deterioration in patients with idiopathic pulmonary fibrosis: causes and assessment. Am J Med 1990; 88:396–404.
21. Bouros D, Hatzakis K, Labrakis H, Zeibecoglou K. Association of malignancy with diseases causing interstitial pulmonary changes. Chest 2002; 121:1278–1289.
22. Akira M, Hamada H, Sakatani M, Kobayashi C, Nishioka M, Yamamoto S. CT findings during phase of accelerated deterioration in patients with idiopathic pulmonary fibrosis. AJR Am J Roentgenol 1997; 168:79–83.
23. Lynch D, Newell J, Logan P, King T, Muller N. Can CT distinguish idiopathic pulmonary fibrosis from hypersensitivity pneumonitis? AJR Am J Roentgenol 1995; 165:807–811.
24. Remy-Jardin M, Remy J, Wallaert B, Muller NL. Subacute and chronic bird breeder hypersensitivity pneumonitis: sequential evaluation with CT and correlation with lung function tests and bronchoalveolar lavage. Radiology 1993; 189:111–118.
25. Katzenstein AL, Fiorelli RF. Nonspecific interstitial pneumonia/fibrosis: histologic features and clinical significance. Am J Surg Pathol 1994; 18:136–147.
26. Travis WD, Matsui K, Moss J, Ferrans VJ. Idiopathic nonspecific interstitial pneumonia: prognostic significance of cellular and fibrosing patterns—survival comparison with usual interstitial pneumonia and desquamative interstitial pneumonia. Am J Surg Pathol 2000; 24:19–33.
27. Park JS, Lee KS, Kim JS, et al. Nonspecific interstitial pneumonia with fibrosis: radiographic and CT findings in seven patients. Radiology 1995; 195:645–648.
28. Kim T, Lee K, Chung M, et al. Nonspecific interstitial pneumonia with fibrosis: high resolution CT and pathologic findings. AJR Am J Roentgenol 1998; 171:1645–1650.
29. Nagai S, Kitaichi M, Itoh H, Nishimura K, Izumi T, Colby TV. Idiopathic nonspecific interstitial pneumonia/fibrosis: comparison with idiopathic pulmonary fibrosis and BOOP. Eur Respir J 1998; 12:1010–1019.
30. Hartman TE, Swensen SJ, Hansell DM, et al. Nonspecific interstitial pneumonia: variable appearance at high-resolution chest CT. Radiology 2000; 217:701–705.
31. Nishiyama O, Kondoh Y, Taniguchi H, et al. Serial high resolution CT findings in nonspecific interstitial pneumonia/fibrosis. J Comput Assist Tomogr 2000; 24:41–46.
32. MacDonald SLS, Rubens MB, Hansell DM, et al. Nonspecific interstitial pneumonia and usual interstitial pneumonia: comparative appearances and diagnostic accuracy of thin-section CT. Radiology 2001; 221:600–605.
33. Lee J, Im J-G, Ahn J, Kim Y, Han M. Fibrosing alveolitis: prognostic implication of ground-glass attenuation at high-resolution CT. Radiology 1992; 184:451–454.
34. Wells AU, Rubens MB, du Bois RM, Hansell DM. Serial CT in fibrosing alveolitis: prognostic significance of the initial pattern. AJR Am J Roentgenol 1993; 161:1159–1165.
35. Ryu JH, Colby TV, Hartman TE, Vassallo R. Smoking-related interstitial lung diseases: a concise review. Eur Respir J 2001; 17:122–132.
36. Hartman TE, Primack SL, Swensen SJ, Hansell D, McGuinness G, Muller NL. Desquamative interstitial pneumonia: thin-section CT findings in 22 patients. Radiology 1993; 187:787–790.
37. Koyama M, Johkoh T, Honda O, et al. Chronic cystic lung disease: diagnostic accuracy of high-resolution CT in 92 patients. AJR Am J Roentgenol 2003; 180:827–835.
38. Heyneman LE, Ward S, Lynch DA, Remy-Jardin M, Johkoh T, Muller NL. Respiratory bronchiolitis, respiratory bronchiolitis-associated interstitial lung disease, and desquamative interstitial pneumonia: different entities or part of the spectrum of the same disease process? AJR Am J Roentgenol 1999; 173:1617–1622.
39. Remy-Jardin M, Remy J, Gosselin B, Becette V, Edme JL. Lung parenchymal changes secondary to cigarette smoking: pathologic-CT correlations. Radiology 1993; 186:643–651.
40. Holt R, Schmidt R, Godwin J, Raghu G. High resolution CT in respiratory bronchi-

olitis-associated interstitial lung disease. J Comput Assist Tomogr 1993; 17:46–50.
41. Park JS, Brown KK, Tuder RM, Hale VA, King TE Jr, Lynch DA. Respiratory bronchiolitis-associated interstitial lung disease: radiologic features with clinical and pathologic correlation. J Comput Assist Tomogr 2002; 26:13–20.
42. Dalphin JC, Debieuvre D, Pernet D, et al. Prevalence and risk factors for chronic bronchitis and farmer's lung in French dairy farmers. Br J Ind Med 1993; 50:941–944.
43. Warren C. Extrinsic allergic alveolitis: a disease commoner in nonsmokers. Thorax 1977; 32:567–573.
44. Muller NL, Guerry-Force ML, Staples CA, et al. Differential diagnosis of bronchiolitis obliterans with organizing pneumonia and usual interstitial pneumonia: clinical, functional, and radiologic findings. Radiology 1987; 162:151–156.
45. Lee KS, Kullnig P, Hartman TE, Muller NL. Cryptogenic organizing pneumonia: CT findings in 43 patients. AJR Am J Roentgenol 1994; 162:543–546.
46. Bouchardy LM, Kuhlman JE, Ball WC Jr, Hruban RH, Askin FB, Siegelman SS. CT findings in bronchiolitis obliterans organizing pneumonia (BOOP) with radiographic, clinical, and histologic correlation. J Comput Assist Tomogr 1993; 17:352–357.
47. Cordier JF, Loire R, Brune J. Idiopathic bronchiolitis obliterans organizing pneumonia: definition of characteristic clinical profiles in a series of 16 patients. Chest 1989; 96:999–1004.
48. Lee J, Lynch D, Sharma S, Brown K, Müller N. Organizing pneumonia: prognostic implication of high-resolution CT features. J Comput Assist Tomogr 2003; 27:260–265.
49. Johkoh T, Muller NL, Taniguchi H, et al. Acute interstitial pneumonia: thin-section CT findings in 36 patients. Radiology 1999; 211:859–863.
50. Ichikado K, Johkoh T, Ikezoe J, et al. Acute interstitial pneumonia: high-resolution CT findings correlated with pathology. AJR Am J Roentgenol 1997; 168:333–338.
51. Desai SR, Wells AU, Rubens MB, Evans TW, Hansell DM. Acute respiratory distress syndrome: CT abnormalities at long-term follow-up. Radiology 1999; 210:29–35.
52. Tomiyama N, Muller NL, Johkoh T, et al. Acute respiratory distress syndrome and acute interstitial pneumonia: comparison of thin-section CT findings. J Comput Assist Tomogr 2001; 25:28–33.
53. Liebow AA, Carrington CB. Diffuse pulmonary lymphoreticular infiltrations associated with dysproteinemia. Med Clin North Am 1973; 57:809–843.
54. Ichikawa Y, Kinoshita M, Koga T, Oizumi K, Fujimoto K, Hayabuchi N. Lung cyst formation in lymphocytic interstitial pneumonitis: CT features. J Comput Assist Tomogr 1994; 18:745–748.
55. Johkoh T, Muller NL, Pickford HA, et al. Lymphocytic interstitial pneumonia: thin-section CT findings in 22 patients. Radiology 1999; 212:567–572.